




Pediatric Lumbar Microdiscectomy

Pediatric Lomber Mikrodiskektomi

 Doğan Güçlühan Güçlü

University of Health Sciences Turkey, Bakırköy Dr. Sadi Konuk Training and Research Hospital, Clinic of Neurosurgery, İstanbul, Turkey

ABSTRACT

Objective: In this study, we will present you a series of lumbar disc herniation (LDH) cases of pediatric age that we had operated using the microdiscectomy method.

Methods: Nine pediatric patients who underwent surgical treatment with microdiscectomy with the diagnosis of LDH by a single surgeon between July 2013 and December 2018 were followed up for approximately 1 year postoperatively, and postoperative low back and leg pain was evaluated with visual analog scale (VAS) score, and operation satisfaction at 1 year was evaluated with MacNab criteria.

Results: The mean age in our study was 14.6. In our study, five patients were operated from L4-5, four patients from L5-S1. The mean of preoperatif VAS was 8.00 ± 0.70 , while the mean of postoperatif VAS was 2.00 ± 0.86 . The difference between VAS scores was statistically significant ($p=0.007$). According to the MacNab score in all of our patients, recovery was evaluated as well and excellent.

Conclusion: Microdiscectomy is a safe and effective treatment for pediatric LDH.

Keywords: Microdiscectomy, pediatric lumbar disc herniation, MacNab

ÖZ

Amaç: Bu çalışmamızda mikrodiskektomi yöntemiyle opere ettiğimiz pediatrik yaş grubu lomber disk hernisi (LDH) olgu serisi sunulacaktır.

Gereç ve Yöntem: Temmuz 2013 ve Aralık 2018 tarihleri arasında tek bir cerrah tarafından LDH tanısıyla mikrodiskektomi ile cerrahi tedavi uygulanan dokuz pediatrik hasta postoperatif olarak yaklaşık 1 yıl süreyle takip edilerek postoperatif bel ve bacak ağrıları vizüel analog skala (VAS) skoru ile, 1. yıl da operasyon memnuniyeti MacNab kriterleri ile değerlendirildi.

Bulgular: Çalışmamızda hastalarımızın yaş ortalaması 14,6 idi. Beş hastamız L4-5, dört hastamız L5-S1 seviyesinden opere edildi. Preoperatif VAS ortalaması $8,00 \pm 0,70$, postoperatif VAS ortalaması $2,00 \pm 0,86$ idi. VAS puanları arasındaki fark istatistiksel olarak anlamlı idi ($p=0,007$). Tüm hastalarımız tarafından MacNab skoruna göre iyileşme iyi/mükemmel olarak değerlendirildi.

Sonuç: Çocukluk çağı disk hernileri tedavisinde mikrodiskektomi güvenli ve etkili bir tedavi yöntemidir.

Anahtar Kelimeler: Mikrodiskektomi, çocukluk çağı lomber disk hernisi, MacNab

Address for Correspondence: Doğan Güçlühan Güçlü, University of Health Sciences Turkey, Bakırköy Dr. Sadi Konuk Training and Research Hospital, Clinic of Neurosurgery, İstanbul, Turkey
E-mail: gucluhang@gmail.com ORCID ID: orcid.org/0000-0002-9959-961X

Cite as: Güçlü DG. Pediatric Lumbar Microdiscectomy. Med J Bakirkoy 2022;18:330-335

Received: 24.07.2022
Accepted: 01.08.2022

INTRODUCTION

Lumbar disc herniation (LDH) has been defined as “the displacement of disc material from intervertebral disc range boundaries, regionally or focally”. Disc herniations that occur in adulthood often develop because of degeneration. LDH is extremely rare in children and adolescents with healthy lumbar vertebrae and intervertebral disks. The incidence of disc herniation in children and adolescents is approximately 0.1%-0.2%. However 0.5%-6.8% of the patients admitted to the hospital with LDH diagnosis are in the age group of child and adolescent. “Lumbar disc protrusion under ten years of age is very rare” this is how it is described in the literature, and the youngest age reported is 13 months (1). Overall, less than 10% of pediatric lower back pain cases are caused by disc herniation, and less than half of these cases require surgery (2,3). Although the pathophysiology of pediatric term LDH is not fully elucidated, risk factors such as trauma, developmental anatomical variants, and genetics play a role in the pathophysiology of pediatric LDH (4-6). In contrast to degenerative discs common in adults, pediatric LDH cases have a lower resorption rate and conservative treatment response due to their higher elasticity and higher liquid content on a nondegenerative background. Open discectomy was widely used until 1980 when the patients unable to perform daily activities due to pain and had progressive neurological deficits that do not benefit from conservative treatment methods. After 80's, minimally invasive surgical methods have been introduced with the advantages of smaller incision sites, less novelization, less bleeding, more limited surgical trauma exposure. The minimally invasive methods used in today's pediatric LDH treatment include microdiscectomy. In this study, we will present you a series of cases with pediatric age LDH operated by microdiscectomy method.

METHODS

In this series of cases: nine pediatric patients under 18 years of age who underwent microdiscectomy operation by a single surgeon, between July 2013 and December 2018. Patients with LDH diagnoses that had been confirmed by physical and neurological examination and magnetic resonance imaging (MRI) examination and patients who did not benefit from at least 2 months of conservative treatment were included. Patients with an acute fracture of the spine due to previous spinal infection or trauma, and the ones with lumbar instability were out of the study. Data were collected both from patient files and electronic medical records. Written consent was obtained from a parent before surgery. The study protocol was approved by the University

of Health Sciences Turkey, Bakırköy Dr. Sadi Konuk Training and Research Hospital's Local Ethics Board (decision no: 2021-16-12, date: 16.08.2021).

Before the operation, demographic data including age and gender, trauma at the onset of symptoms, heavy lifting, family history, intense sports activity and whether there was lower back pain-accompanying leg pain in the form of radiculopathy was questioned. During the pre-operation examination, straight leg lift test, lower limb weakness and loss of sensation were recorded and lumbar MRI and in some cases, computed tomography and dynamic radiographs were taken if necessary before the operation to confirm LDH level and side location. Pain was scored according to the visual analog scale (VAS).

The operation records were reviewed for blood loss, complications and postoperative hospitalization. All patients were followed for a period of at least 1 year and postoperative lower back and leg pain were graded with the VAS score. Operation satisfaction was assessed by the MacNab criteria one year after surgery. According to the MacNab criteria: excellent (4): no pain, no work restrictions, good (3): lower back and leg pain, no obstacles to work, medium (2): occasional pain, but unable to continue his job, bad (1): pain, the need for a second surgery (7).

Statistical Analysis

Statistical analysis was performed using IBM SPSS 22.0 for Windows statistical software (IBM Corp., Armonk, NY). Statistical significance was considered as $p < 0.05$. Descriptive statistical methods including mean, standard deviation were used. The Wilcoxon test was used to evaluate the difference between pre- and postoperative VAS scores.

Surgical Technique

All patients were operated on in the prone position under general anesthesia after preoperative prophylactic antibiotic therapy. Before the operation, distance control was performed using the C-arm scopy. A 1.5-2.0 cm long skin incision was made in the middle line. The dorsolomber fascia was opened 5 mm laterally from the midline. Paravertebral muscles were removed from medial to lateral by maintaining the facet capsule integrity and taking care not to cross the lateral border of the facet without cutting the adhesion site of the spinous process. The accuracy of the distance was checked again with the C-arm scopy. Caspar microdiscectomy retractor has been inserted. Microscopically, the interlaminar distance is exposed. Partial hemilaminectomy was performed using high-speed drill and Kerrison. To reduce postop epidural fibrosis, the nerve root was identified by preserving the league flavum as much

as possible. The size of the disc herniation was observed by gently excluding the nerve root medially by avoiding continuous ecartation. Aggressive discectomy was avoided as reducing disc height could lead to segmental instability, and only the extracted disc fragment was removed. If the annular defect was large, discectomy was performed. If the annular defect was small and the annulus was stable, the normal disc tissue was preserved and fragmentectomy and annuloplasty were performed. The lumbodorsal fascia was closed subcutaneously with 2/0 absorbed suture, with 4/0 absorbed suture under the skin, the skin closed subcutaneously with 4/0 absorbed suture.

RESULTS

Six of our patients were girls (66.6%) and three of them were boys (33.3%) The mean age in our study was 14.6 (+/-1) The youngest was 13 and the eldest was 16 years old. All of our patients were operated with a single distance LDH diagnosis. Three patients were operated from the level of right L4-5, two patients from left L4-5, two patients from right and left L5-S1 with five patients from L4-5 (55%) and four patients operated from L5-S1 (44%) (Figure 1). The average duration of symptoms in our patients was 3.7 months. There were trauma history in four patients (44%), heavy lifting in three patients (33%) and family history in three patients (33%) in lumbar disc hernia etiopathogenesis (Figure 2). All of our patients had leg pain, 5 patients (55%) had leg pain complaints accompanied by back pain. All of our patients tested positive for straight leg lift test. The neurological examination of 4 patients (44%) showed muscle weakness. The mean duration of hospitalization was 1.4 (+/-1.6) days (Table 1).

All of our patients had intraoperative blood loss under 50 mL. Mean preoperative VAS score was 8 (+/-1) mean postoperative VAS score was 2 (+/-1), improvement in preoperative and postoperative VAS score was 6. The mean of preoperatif VAS was 8.00 ± 0.70 , while the mean of postoperatif VAS was 2.00 ± 0.86 . According to the Wilcoxon test, the significance of the difference between these two averages was calculated as $(Z) -2,719$ and the difference between VAS preoperative and postoperative scores was statistically significant ($p=0.007$). According to the MacNab score in all of our patients, recovery was evaluated as good and excellent (Table 2). As a complication, an early superficial infection was observed in a patient and had recovered with oral antibiotic treatment.

DISCUSSION

On average, 10% of children with low back pain have disc herniation, and less than half need surgical intervention as a treatment method (3). The ideal treatment for pediatric LDH is controversial (8,9). Many clinicians recommend conservative treatment as the primary treatment, except for patients with cauda equina syndrome, patients with rapidly developing neurological deficits. Surgery is recommended when conservative treatment fails despite being administered for several months. Some studies have found that LDH in children has a lower success rate of conservative treatment compared to adults (4,10). 25-50% improvement was reported in pediatric LDH patients with no neurological symptoms, who were treated conservatively and monitored for a long time (11). 42% of the pediatric and adolescent group who had been treated by epidural steroid injection with the diagnosis of LDH needed surgical treatment (12). This is explained by the fact that pediatric

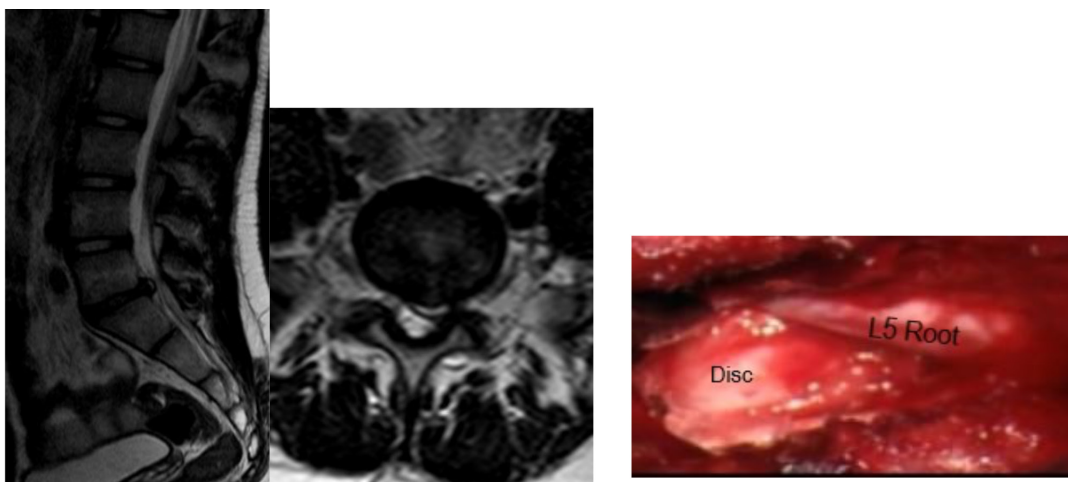


Figure 1. Fifteen years old left L5-S1 HNP; sagittal T2, axial T2 and intraoperative imaging
HNP: Herniated nucleus pulposus

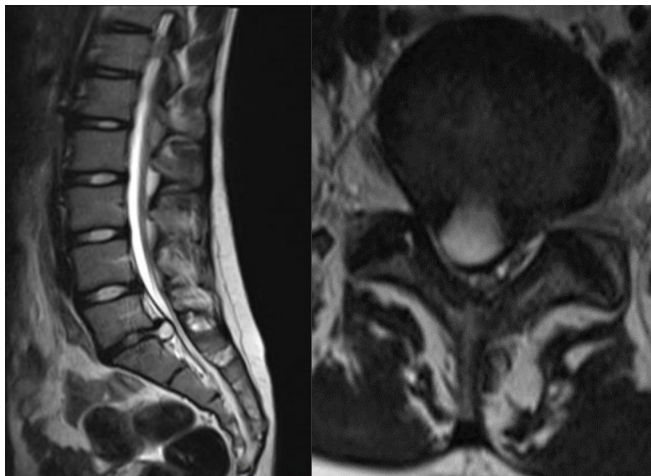


Figure 2. Fourteen years old right L5-S1 traumatic disc herniation

patients are more difficult to adapt to absolute bed rest and are probably accompanied by large annular tear when develop after trauma. Besides, the herniated disc segment is less degenerated compared to adults and the disc is more difficult to absorb due to its hydration and gelatin structure (13). In 1945, Wahren (14) published the case of a 12-year-old gymnast girl who did not benefit from one month of conservative treatment as the first pediatric disc hernia to be surgically operated with the diagnosis of right L5-S1.

The mean age in our study was 14.6 (+/-1) The youngest was 13 years old and the oldest was 16 years old. Similar to our findings, LDH was observed in 97.5% between 13 and 18 and 2.5% under 12 (15). LDH under twelve years of age had defined very rarely in the literature (16). No cases operated under 12 years in our series. During the last 30 years, only 8 surgical cases under 10 years of age have been published (17).

In our study, 6 of our patients were female (66.6%) and 3 (33.3%) were male. Similar to our results, McAvoy et al. (18) reported that 111 of 199 pediatric patients (55.8%) who underwent microdiscectomy were reported as girls. Another series of pediatric cases that underwent lumbar discectomy reported 58% of the patients as girls (19). While girls undergo puberty and hence, the growth rate peaks between 11 and 15 years old, this process is between 13 and 17 years old for boys. Bone and ligaments mature earlier in women. Here, it has been emphasized that LDH is more common in female patients due to early onset of degeneration than in males by completing maturation at an early age. In our study, LDH etiopathogenesis had trauma in four patients (44%), heavy lifting in three patients (33%) and family history in three patients (33%). The rate of trauma history in patients with childhood LDH varies between 8% and 82% in the literature (20). In some studies, it has been stated that trauma is not the main factor, but it increases the current disease and makes it symptomatic (21,22). 13%-57% of pediatric cases reported that there was also LDH in their first degree family members. In a study by Theodore et al. (23), 80% of childhood disc hernias had mutations in the structure that encode collagen.

In our study, five patients were operated from L4-5 (55%) to four patients from L5-S1 (44%). A study by Raghu et al. (17) reported that LDH in children and adolescents treated with surgery was frequent (52%) at levels L4-5 and (41%) L5-S1 (19). In-wide sample follow-up studies, L4-5 levels (60.3%), L5-S1 (42.7%) and L3-4 (9.5%) were indicated in order of frequency (20). The most commonly affected distance in the adult age group has been reported as L5-S1 (24).

In our study, while all of our patients had leg pain, five patients (55%) complained of lower back pain. Ozgen et al. (25) reported that 88% of patients had low back pain,

Table 1. Socio-demographic and clinical variables

Age	Gender	Level	Side	Cause	FH	SLLT	Motor deficit	Pain locazition	Pain duration	HS/day
13	F	L4-5	R	TH	-	10	-	Leg	6 m	2
16	F	L5-S1	L	HL	-	20	-	Leg + Back	3 m	2
15	M	L5-S1	R	HL	-	45	PF 4/5	Leg	3 m	1
14	F	L4-5	L	TH	-	30	EHL 4/5	Leg + Back	2 m	2
16	F	L4-5	L	HL	+	30	EHL 4/5	Leg	5 m	1
14	F	L5-S1	R	-	+	45	-	Leg	6 m	1
15	M	L4-5	R	-	+	30	-	Leg + Back	4 m	1
15	F	L5-S1	L	TH	-	30	-	Leg + Back	3 m	1
14	M	L4-5	R	TH	-	45	DF4/5	Leg + Back	2 m	2

F:Female, M: Male, R: Right, L: Left, HL: Heavy lifting, TH: Trauma history, FH: Family history, m: Month, SLLT: Straight leg lift test, HS: Hospital stay

Table 2. Preoperative and postoperative VAS and MacNab scores

VAS Preop	VAS Postop	MacNab
9	2	4
8	2	3
8	3	3
8	2	3
8	3	3
7	1	4
8	1	4
9	3	3
7	1	4

VAS: Visual analog scale

whereas 35% had sciatic pain spread. McAvoy et al. (18) reported that 98.0% of cases were referred by radicular pain with 66.3% lower back pain.

In our study, muscle weakness was detected in 4 patients (44%) who tested positive for straight leg lift test during neurological examination. In patients with low back pain and radiculopathy, the sensibility of this test was found to be higher than expected in the pediatric age group (26). In the adult age group, it has been reported that the sciatic nerve, which is less mobilized due to peridural adhesion, is important in the formation of pain in the straight leg lift test (27). McAvoy et al. (18) evaluated the straight leg lift test as 98.9% positive in their study in the Pediatric Group. Older patients have less mobile sciatic nerves, related to peridural fibrotic adhesions, which are thought to be important for pain generation on straight leg raising (18).

About 90% of symptomatic disc herniation occurs at vertebra levels L4-L5 and L5-S1. Disc herniation in L4-L5 most commonly affects the L5 nerve root. The weakness of the extensor hallucis longus muscle can be seen with L5 nerve root compression. Sensory abnormalities can be seen in the dorsal part of the foot. There was no deep tendon reflex associated with the L5 nerve root. The S1 nerve root is most commonly affected by disc herniation in L5-S1. S1 nerve root compression can cause plantar flexion and eversion of the ankle to weaken. The Achilles tendon reflex must be tested because S1 is an indicator of nerve root function. Cahill et al. (15) found lower limb motor weakness in 26% of patients, decreased sensation in 41%, and deep tendon reflex loss in 22%. In the study by McAvoy et al. (18), sensory changes were reported as 32%, lower limb motor weakness, and loss of deep tendon reflexes as 19.0% and

18.5%, respectively. Raghu et al. (17) had determined motor deficits loss to be 43%.

In our study mean preoperative VAS score was 8 (+/-1) mean postoperative VAS score was 2 (+/-1). Mean improvement in VAS score in the postoperative first year was found to be. All of our patients in post-operative first year rated their improvement as good/excellent. The recovery and long-term prognosis in pediatric patients is much better than in adults (27). Çelik et al. (28) compared 32 pediatric and adult patients who underwent lumbar microdiscectomy. It has been reported that a significant decrease in pain in the pediatric group in the short- and long term follow-up furthermore, reherniation and postoperative epidural fibrotic changes were reported to be higher in the adult group (28). In a Swedish study, it was shown that leg and back pain was significantly reduced in the pediatric group after surgery compared with adults at 1 or 2 years of follow-up (average =1.7 years) (29). In 2019, a study by McAvoy et al. (18) also reported surgical satisfaction as good and excellent in 90% of 199 pediatric cases.

The mean duration of hospitalization in our study was 1.4 (+/-1.6) days. Intraoperative blood loss in all our patients was under 50 mL. An early superficial infection in a patient who had been treated with oral antibiotics. Perioperative (1.0%), and postoperative (2.6%) complications with microdiscectomy applied in the pediatric age group are rare in the literature. Studies show (17,26) low rates of deep and superficial infection in pediatric degenerative spine surgery (<1%) and minimally invasive techniques are associated with lower infection rates than open surgery (30).

CONCLUSION

Childhood disc hernias are a fairly rare clinical condition. If there is a significant and/or progressive neurological deficit and no response with conservative treatment, microdiscectomy is a safe and effective treatment.

ETHICS

Ethics Committee Approval: The study protocol was approved by the University of Health Sciences Turkey, Bakırköy Dr. Sadi Konuk Training and Research Hospital's Local Ethics Board (decision no: 2021-16-12, date: 16.08.2021).

Informed Consent: Written consent was obtained from a parent before surgery.

Financial Disclosure: The author declared that this study received no financial support.

REFERENCES

1. MacGee EE. Protruded lumbar disc in a 9-year-old boy. *J Pediatr* 1968;73:418-9.
2. Carey TS, Garrett J, Jackman A, McLaughlin C, Fryer J, Smucker DR. The outcomes and costs of care for acute low back pain among patients seen by primary care practitioners, chiropractors, and orthopedic surgeons. The North Carolina Back Pain Project. *N Engl J Med* 1995;333:913-7.
3. Durham SR, Sun PP, Sutton LN. Surgically treated lumbar disc disease in the pediatric population: an outcome study. *J Neurosurg* 2000;92(1 Suppl):1-6.
4. Kurihara A, Kataoka O. Lumbar disc herniation in children and adolescents. A review of 70 operated cases and their minimum 5-year follow-up studies. *Spine (Phila Pa 1976)* 1980;5:443-51.
5. DeLuca PF, Mason DE, Weiand R, Howard R, Bassett GS. Excision of herniated nucleus pulposus in children and adolescents. *J Pediatr Orthop* 1994;14:318-22.
6. Bradford DS, Garcia A. Herniations of the lumbar intervertebral disk in children and adolescents. A review of 30 surgically treated cases. *JAMA* 1969;210:2045-51.
7. Macnab I. Negative disc exploration. An analysis of the causes of nerve-root involvement in sixty-eight patients. *J Bone Joint Surg Am* 1971;53:91-903.
8. Dang L, Liu Z. A review of current treatment for lumbar disc herniation in children and adolescents. *Eur Spine J* 2010;19:205-14.
9. Dang L, Chen Z, Liu X, Guo Z, Qi Q, Li W, et al. Lumbar Disk Herniation in Children and Adolescents: The Significance of Configurations of the Lumbar Spine. *Neurosurgery* 2015;77:954-9.
10. Kurth AA, Rau S, Wang C, Schmitt E. Treatment of lumbar disc herniation in the second decade of life. *Eur Spine J* 1996;5:220-4.
11. Zamani MH, MacEwen GD. Herniation of the lumbar disc in children and adolescents. *J Pediatr Orthop* 1982;2:528-33.
12. Kurgansky KE, Rodriguez ST, Kralj MS, Mooney JJ, Dinakar P, d'Hemecourt PA, et al. Epidural Steroid Injections for Radiculopathy and/or Back Pain in Children and Adolescents: A Retrospective Cohort Study With a Prospective Follow-Up. *Reg Anesth Pain Med* 2016;41:86-92.
13. Dang L, Liu Z. A review of current treatment for lumbar disc herniation in children and adolescents. *Eur Spine J* 2010;19:205-14.
14. WAHREN H. Herniated nucleus pulposus in a child of twelve years. *Acta Orthop Scand* 1945;16:40-2.
15. Cahill KS, Dunn I, Gunnarsson T, Proctor MR. Lumbar microdiscectomy in pediatric patients: a large single-institution series. *J Neurosurg Spine* 2010;12:165-70.
16. Revuelta R, De Juambelz PP, Fernandez B, Flores JA. Lumbar disc herniation in a 27-month-old child. Case report. *J Neurosurg* 2000;92(1 Suppl):98-100.
17. Raghu ALB, Wiggins A, Kandasamy J. Surgical management of lumbar disc herniation in children and adolescents. *Clin Neurol Neurosurg* 2019;185:105486.
18. McAvoy M, McCrea HJ, Chavakula V, Choi H, Bi WL, Mekary RA, et al. Long-term outcomes of lumbar microdiscectomy in the pediatric population: a large single-institution case series. *J Neurosurg Pediatr* 2019:1-9.
19. Strömqvist F, Strömqvist B, Jönsson B, Gerdhem P, Karlsson MK. Lumbar disc herniation surgery in children: outcome and gender differences. *Eur Spine J* 2016;25:657-63.
20. Karademir M, Eser O, Karavelioglu E. Adolescent lumbar disc herniation: Impact, diagnosis, and treatment. *J Back Musculoskelet Rehabil* 2017;30:347-52.
21. Parisini P, Di Silvestre M, Greggi T, Miglietta A, Paderni S. Lumbar disc excision in children and adolescents. *Spine (Phila Pa 1976)* 2001;26:1997-2000.
22. Kumar R, Kumar V, Das NK, Behari S, Mahapatra AK. Adolescent lumbar disc disease: findings and outcome. *Childs Nerv Syst* 2007;23:1295-9.
23. Theodore N, Ahmed AK, Fulton T, Mousses S, Yoo C, Goodwin CR, et al. Genetic Predisposition to Symptomatic Lumbar Disk Herniation in Pediatric and Young Adult Patients. *Spine (Phila Pa 1976)* 2019;44:E640-9.
24. Gulati S, Madsbu MA, Solberg TK, Sørlie A, Giannadakis C, Skram MK, et al. Lumbar microdiscectomy for sciatica in adolescents: a multicentre observational registry-based study. *Acta Neurochir (Wien)* 2017;159:509-16.
25. Ozgen S, Konya D, Toktas OZ, Dagcinar A, Ozek MM. Lumbar disc herniation in adolescence. *Pediatr Neurosurg* 2007;43:77-81.
26. Tabesh H, Tabesh A, Fakharian E, Fazel M, Abrishamkar S. The effect of age on result of straight leg raising test in patients suffering lumbar disc herniation and sciatica. *J Res Med Sci* 2015;20:150-3.
27. Slotkin JR, Mislow JM, Day AL, Proctor MR. Pediatric disk disease. *Neurosurg Clin N Am* 2007;18:659-67.
28. Çelik S, Göksu K, Çelik SE, Emir CB. Benign neurological recovery with low recurrence and low peridural fibrosis rate in pediatric disc herniations after lumbar microdiscectomy. *Pediatr Neurosurg* 2011;47:417-22.
29. Lagerbäck T, Elkan P, Möller H, Grauers A, Diarbakerli E, Gerdhem P. An observational study on the outcome after surgery for lumbar disc herniation in adolescents compared with adults based on the Swedish Spine Register. *Spine J* 2015;15:1241-7.
30. Smith JS, Shaffrey CI, Sansur CA, Berven SH, Fu KM, Broadstone PA, et al. Rates of infection after spine surgery based on 108,419 procedures: a report from the Scoliosis Research Society Morbidity and Mortality Committee. *Spine (Phila Pa 1976)* 2011;36:556-63.