



Research

Ex Vivo Ureteroscopy of Living Donor Kidneys: A Single Center Experience

Canlı Donör Böbreklerinde *Ex Vivo* Üreteroskopi: Tek Merkez Deneyimleri

 Serdar Karadağ,  Ubeyd Sungur

University of Health Sciences Turkey, Bakırköy Dr. Sadi Konuk Training and Research Hospital, Clinic of Urology, Istanbul, Turkey

ABSTRACT

Objective: In this study, by reviewing the cases who underwent *ex vivo* ureterorenoscopy (exURS) and laser lithotripsy as a bench procedure after nephrectomy of living donors with kidney stones at our clinic, the results were presented.

Methods: The data of 13 donors who had exURS between 2015 and 2021 were analyzed retrospectively. The demographic characteristics of the donors who underwent exURS laser lithotripsy, stone properties, postoperative stone-free rate, recurrence, graft functions and surgical technique were examined.

Results: The mean age was 34.7 ± 5.4 years and the male-to-female ratio was 8:5. The mean stone size was 5.7 ± 1.2 mm. Based on stone locations the number of donors was 1 (7.7%), 4 (30.8%) and 8 (61.5%) in the upper, middle and lower calyces, respectively. Surgical procedures were carried out successfully for all donors and the mean operative time was recorded as 9.4 ± 1.3 min. No postoperative complications occurred in cases. The mean creatinine value of the recipients at postoperative month 1 was 1.1 ± 0.6 mg/dL. No recurrence was observed during an average follow-up period of 26 months (range, 7 to 58 months).

Conclusion: Our experiences demonstrate that exURS is a simple and safe practical operative procedure enabling stone-free status without any effect on allograft function. Studies with large numbers of participants and long follow-up periods would be useful in contributing to the literature.

Keywords: *Ex vivo* surgery, renal transplantation, ureteroscopy, urolithiasis

ÖZ

Amaç: Bu çalışmada kliniğimizde böbrek taşına sahip canlı donörlerde donör nefrektomiden sonra bench masasında *ex vivo* üreterorenoskopi (exURS) ve lazer litotripsi uygulanan vakalar incelenerek olguların sonuçları paylaşıldı.

Gereç ve Yöntem: 2015-2021 arasında exURS yapılan 13 hastanın verileri retrospektif olarak incelendi. exURS lazer litotripsi uygulanan donörlerin demografik bilgileri, taş özellikleri, postoperatif dönemde taşsızlık oranı, rekürrens, greft fonksiyonları ve cerrahi teknik incelenerek analiz edildi.

Bulgular: Ortalama yaş $34,7 \pm 5,4$ ve erkek-kadın oranı 8:5 idi. Ortalama taş boyutu $5,7 \pm 1,2$ mm idi. Taş lokalizasyonuna göre incelendiğinde böbrek üst, orta ve alt polde olmak üzere sırasıyla 1 (%7,7), 4 (%30,8) ve 8 (%61,5) donör mevcuttu. Tüm hastalara başarılı bir şekilde cerrahi prosedür uygulandı ve ortalama operasyon süresi $9,4 \pm 1,3$ dakika saptandı. Hiçbir hastada postoperatif komplikasyon gelişmedi. Alıcıların 1. ayda ortalama kreatinin değeri $1,1 \pm 0,6$ idi. Ortalama 26 aylık (7-58 ay) takip süresinde rekürrens görülmedi.

Sonuç: Deneyimlerimiz *ex vivo* URS'nin allograft fonksiyonunu etkilemeden, taşsızlığın sağlandığı, kolay ve güvenli olarak uygulanabilir bir yöntem olduğunu ortaya koydu. Geniş hasta sayılı ve uzun takip süreli çalışmalar literatüre katkı sağlayacaktır.

Anahtar Kelimeler: *Ex vivo* cerrahi, renal transplantasyon, üreterorenoskopi, ürolitiazis

Address for Correspondence: Ubeyd Sungur, University of Health Sciences Turkey, Bakırköy Dr. Sadi Konuk Training and Research Hospital, Clinic of Urology, Istanbul, Turkey
Phone: +90 553 495 7980 E-mail: ubeydsungur@gmail.com ORCID ID: orcid.org/0000-0002-8910-9859

Cite as: Karadağ S, Sungur U. *Ex Vivo* Ureteroscopy of Living Donor Kidneys: A Single Center Experience. Med J Bakirkoy 2022;18:108-112

Received: 20.02.2022
Accepted: 07.03.2022

INTRODUCTION

Renal transplantation is the treatment method regarded as the gold standard in patients with end-stage renal disease (ESRD) (1). It is also known that life expectancy after transplant is higher compared to patients receiving hemodialysis and the quality of life has increased significantly (2).

Whilst the number of patients with ESRD on the kidney transplant waiting list continues to rise, no adequate increase has been observed with respect to the number of donors (3). This has ensured that people with a history of hypertension, diabetes, or nephrolithiasis may be considered as “marginal donors” following risk calculations. The donor evaluation criteria of the Amsterdam forum state that the presence of a single calculus below 1.5 cm without nephrocalcinosis on computed tomography (CT) examinations may be accepted as a donor in the absence of any metabolic abnormality or urinary infection (4). Upon recognition of the individuals with a history of urolithiasis as donors, a 5% increase in the number of kidney transplants has been reported (5). Hence, stone surgery in donor kidneys or renal transplantation (RT) is expected to be performed for many cases over the coming years.

As the presence of calculi in the transplanted kidney may lead to outcomes such as obstruction, sepsis and graft loss, its treatment is important. Management of stones less than 4 mm may be by monitoring. Extracorporeal shock wave lithotripsy (ESWL) or retrograde intrarenal surgery (RIRS) is an alternative before transplantation in treating calculi between 4 and 15 mm. Recently, some authors have stated that *ex vivo* stone surgery on the side bench is an option after donor nephrectomy (6-8).

In this study, we published the data and follow-up results of donors who underwent *ex vivo* bench surgery using semirigid ureterorenoscopy (URS) and laser lithotripsy after donor nephrectomy at our center.

METHODS

Following the receipt of Ethics Committee approval numbered 2021/527 from Bakirkoy Dr. Sadi Konuk Training and Research Hospital (decision no: 2021-22-21, date: 15.11.2021), a review was conducted retrospectively on patients who had living donor kidney transplantation between the dates of January 2015 and October 2021. During RT operation, individuals who underwent stone surgery performed as *ex vivo* bench procedure via laser lithotripsy using semirigid URS were identified (n=13). General donor assessment was applied to the kidney donors. By screening all donors with urolithiasis for

metabolic risk factors in accordance with the European Urology Association guideline recommendations, it was determined that there was no hypocitraturia, hypercalciuria, hyperoxaluria and hyperuricosuria (9). Informed consent was obtained from all donors and renal recipients by providing information related to the risk of calculus recurrence in their kidneys after transplantation and the potential adverse events.

Ex vivo ureterorenoscopy (exURS) was not performed for asymptomatic calculi below 4 mm, instead an *in vivo* double J (DJ) stent was routinely placed into the kidney after transplantation. Therefore, donors with single calculus ranging between 4 and 15 mm identified on CT angiography examinations and who underwent URS with laser lithotripsy as an *ex vivo* bench procedure were included in the study (Figure 1). Along with demographic characteristics of the donors such as age and gender, stone size, stone location, stone fragmentation time, operation time, and postoperative stone-free rate were recorded and monitoring the recipients for stone recurrence and renal allograft functions.

Statistical analysis was not performed in our study.

Ex Vivo Bench URS

Immediately following donor nephrectomy, the kidney was stored in ice on the side bench, and retrograde URS was carried out under low pressure (by placing the irrigation bag at a maximum of 50 cm above kidney level) and manual irrigation with normal saline not using a guidewire. Firstly, the ureter was straightened by spatulation and the distal part was stabilized with permanent sutures. The ureteroscope was then advanced from the ureter into the renal pelvis. The device used was a 7.5 semi rigid ureteroscope (Karl Storz, Germany). While examining the pelvicalyceal system, the kidney was manipulated with the free hand for better

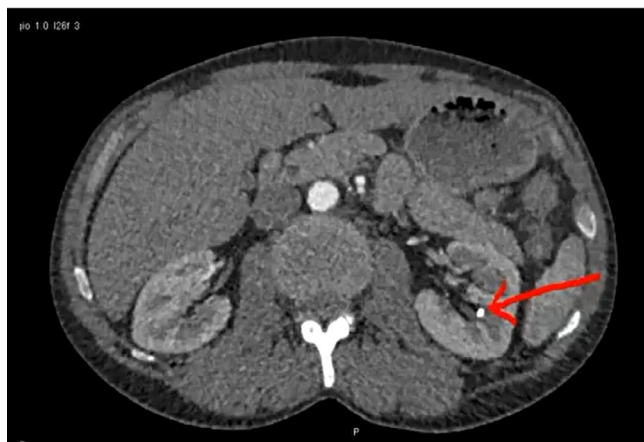


Figure 1. Computed tomography image of 6 mm calculus in the middle pole of left donor kidney as pointed by arrow

visualization of the calculus. In response to the possibility of being unable to reach the pelvis with the semirigid ureteroscope, a 7.5 Fr flexible ureteroscope (F-URS) (UF30 Zhuhai Vision Medical Technology Co., Ltd., China) was set ready for use yet F-URS was not needed. The detected stones were fragmented using 500 mm fiber holmium: yttrium aluminum garnet (Ho:YAG) laser lithotripsy and extracted with endoscopic stone removal forceps.

RESULTS

A total of 13 donors were included in the study following the application of inclusion and exclusion criteria. The female to male-donor ratio was 5:8. The mean stone size was 5.7 ± 1.2 mm. Laser lithotripsy with 7.5 Fr semirigid URS was carried out by a single surgeon (S.K.) for all patients. The average operation time was calculated as 9.4 ± 1.3 min. No complications were observed during or after the surgery. Following transplantation, DJ catheter was removed from the recipients 1 month post procedure and the mean serum creatinine was measured as 1.1 ± 0.6 mg/dL at postoperative month 1. The average long-term follow-up period was 26 months (7-58 months). During follow-up, no recurrence or ureteral stenosis was identified in any patient (Table 1).

DISCUSSION

The selection of suitable donor-recipient pairs is a critical step for a successful kidney transplantation (10). With the spread of minimally invasive kidney surgery over the years, the enlargement of the donor pool has allowed individuals with small renal masses or kidney stones to be living kidney donor candidates as "marginal donors" (11,12). Extensive use of CT angiography in diagnostic studies of living kidney donors has led to greater detection of small asymptomatic kidney stones (13).

In previous studies, nephrolithiasis was a relative contraindication for kidney transplantation (in case of both deceased and living donors) due to the risk of stone formation, which may result in recurrent infections, urinary obstruction and graft loss (14).

During the Amsterdam Forum on the care of the live kidney donor in 2004, it was established that asymptomatic potential donors with a history of single renal calculus could be candidates if they met the following criteria; (a) absence of hypercalciuria, hyperuricemia, metabolic acidosis; (b) absence of cystinuria and hyperoxaluria; (c) the size of existing stone < 15 mm and assessed as potentially removable during extraction (4).

As calculi less than 4 mm in size can be followed up due to high spontaneous passage rate, bench URS arises as a recommended treatment option with respect to 4-15 mm stones (15). Thus, the question of when stone-oriented treatment should be applied in transplants carried out from donors with a history of urolithiasis has emerged. Whilst ESWL or RIRS is an option before transplant, performing RT along with successful stone fragmentation using 6.9 Fr semirigid URS as a bench procedure right after kidney removal in a single session has been firstly mentioned in a case study of 10 patients conducted by Rashid et al. (8) in 2004. Pushkar et al. (16) reported that the extraction of the stone was done by pyelotomy after reaching the calculus via exURS and manipulating the renal pelvis with a basket. Ganpule et al. (7) used a 6 Fr pediatric cystoscope for exURS and obtained successful results. Olsburgh et al. (5) performed exURS using a laser and a basket with 7.5 Fr F-URS.

Numerous different surgical methods are described because of the variety in devices and techniques used, and it is evident that favorable outcomes have been achieved. Stone-free rate is reported to be between 89.5% and 100% in the literature (17). There are several views on the choice of technique and device to be used. Olsburgh et al. (5) have stated that the best option with respect to the operative management of potential living kidney donors with a history of stones is exURS using F-URS. However, it

Table 1. Demographic characteristics, stone characteristics and outcomes of ex vivo ureteroscopy

Parameters (mean \pm SD)	Total (n=13)
Age (years)	34.7 \pm 5.4
Gender (n; %)	
Male	8 (61.5)
Female	5 (38.5)
Laterality (n; %)	
Left	11 (84.6)
Right	2 (15.4)
Stone size (milimeter)	5.7 \pm 1.2
Stone location (n; %)	
Upper calyx	1 (7.7)
Middle calyx	4 (30.8)
Lower calyx	8 (61.5)
Operation time (minutes)	9.4 \pm 1.3
Serum creatinine at postop month 1	1.1 \pm 0.6
Follow-up time (months) *	26 (7-58)

*Presented as median (interquartile range), SD: Standart deviation

has been expressed by Pushkar et al. (16) that the use of semi-rigid URS is easier compared to F-URS. The ease of renal manipulation by hand along with the ureteral mobility simplifies the use of semi-rigid URS. In the study by Sarier et al. (17), it has been noted that successful results are obtained with the pediatric cystoscope as it enables better stability and maneuver capability due to shorter shaft length.

We believe that semi-rigid URS should be preferred first because of easier use and short operative time, yet F-URS may be used in cases of acute angulation or difficulty accessing the stone. It has been demonstrated that use of laser in lithotripsy is safer than pneumatic due to the risk of mucosal injury (16).

Operative time is an important issue that needs to be addressed in kidney transplantation. A cold ischemia period of more than 8 h has the potential to cause harm to post-transplant renal function and increase acute rejection rates and affect long-term graft survival (16). However, upon reviewing exURS times, it was observed that the time interval spent for stone surgery was quite short and usual does not exceed 30 min. In our study, the mean operation time was calculated as 9.4 ± 1.3 min.

Whilst exURS includes potential risks such as hematuria, graft dysfunction, urinary leakage and ureteral trauma, morbidity and complication rates are not revealed to be high on the examination of the literature (15). Mosimann et al. (18) reported a case of graft loss following exURS due to acute ischemia caused by a major intimal flap at the hilum. It was thought that this complication occurred because of URS manipulations within the renal pelvis, leading to an injury of the adjacent artery. Therefore, they recommended considering pyelolithotomy as an alternative to exURS, depending on the clinical circumstances (18).

On a systematic review published by Longo et al. (15) recently, it has been shown that the incidence of short-term complications for exURS is low. It stated that two (22%) of 9 early postoperative complications were due to URS. One of them was noted to be urinary leakage repaired by a primary suture after pyelolithotomy and the other one was complete occlusion of the ureteroneocystostomy treated with revision of the ureteroneocystostomy (15).

During *ex vivo* endourological procedures, manual manipulation of the ureter at minimal level may be applied to avoid ureteral injury and the lowest irrigation fluid flow as well as the use of a DJ ureteral stent might be considered to prevent pyelovenous and pyelolymphatic reflux (7). In our study, no complications were identified in any patient during the early postoperative period and long-term follow-up.

In a previously published series, it was revealed that none of the patients had stone recurrence during follow-up. The role of metabolic factors in stone formation and the importance of metabolic assessment with regard to donor selection should not be overlooked. Also in our study, no recurrence was observed in any patient during the average follow-up period of 2 years. As the number of exURS procedures increases, long-term data along with long follow-up periods will be available. The limitations of our study include its retrospective nature, being performed by one surgeon in a single center, and the small number of cases.

CONCLUSION

We obtained results supporting that *ex vivo* semi rigid URS may be carried out easily and safely during RT in eligible living kidney donors who have kidney stones, without any impact on allograft function. Easier manipulation of semi rigid URS on the side bench and manual handling of the kidney enable lithotripsy to be performed successfully, not affecting cold ischemia times. In the future, studies with many patients and long follow-up periods would contribute to the literature.

ETHICS

Ethics Committee Approval: This study was approved by the Institutional Ethics Committee of Bakırköy Dr. Sadi Konuk Training and Research Hospital (decision no: 2021-22-21, date: 15.11.2021).

Informed Consent: Informed consent was obtained from all donors and renal recipients by providing information related to the risk of calculus recurrence in their kidneys after transplantation and the potential adverse events.

Authorship Contributions

Surgical and Medical Practices: S.K., Concept: S.K., U.S., Design: S.K., Data Collection or Processing: U.S., Analysis or Interpretation: S.K., U.S., Literature Search: S.K., U.S., Writing: U.S.

Conflict of Interest: The authors declare that they have no conflict of interest.

Financial Disclosure: The authors declared that this study received no financial support.

REFERENCES

1. Magee JC, Barr ML, Basadonna GP, Johnson MR, Mahadevan S, McBride MA, et al. Repeat organ transplantation in the United States, 1996-2005. *Am J Transplant* 2007;7:1424-33.
2. Kabbalo MA, Canney M, O'Kelly P, Williams Y, O'Seaghda CM, Conlon PJ. A comparative analysis of survival of patients on dialysis and after kidney transplantation. *Clin Kidney J* 2018;11:389-93.

3. Delmonico FL, Dew MA. Living donor kidney transplantation in a global environment. *Kidney Int* 2007;71:608-14.
4. Delmonico F; Council of the Transplantation Society. A Report of the Amsterdam Forum On the Care of the Live Kidney Donor: Data and Medical Guidelines. *Transplantation* 2005;79(6 Suppl):S53-66.
5. Olsburgh J, Thomas K, Wong K, Bultitude M, Glass J, Rottenberg G, et al. Incidental renal stones in potential live kidney donors: prevalence, assessment and donation, including role of ex vivo ureteroscopy. *BJU Int* 2013;111:784-92.
6. Martin G, Sundaram CP, Sharfuddin A, Govani M. Asymptomatic urolithiasis in living donor transplant kidneys: initial results. *Urology* 2007;70:2-5; discussion 5-6.
7. Ganpule A, Vyas JB, Sheladia C, Mishra S, Ganpule SA, Sabnis RB, et al. Management of urolithiasis in live-related kidney donors. *J Endourol* 2013;27:245-50.
8. Rashid MG, Konnak JW, Wolf JS Jr, Punch JD, Magee JC, Arenas JD, et al. Ex vivo ureteroscopic treatment of calculi in donor kidneys at renal transplantation. *J Urol* 2004;171:58-60.
9. EAU Guidelines on Urolithiasis 2021. *Eur Assoc Guidel* 2021 Ed. 2021; <https://uroweb.org/guideline/renal-transplantation/#3>. (Accessed on 18/2/2022).
10. Mehra NK, Chopra GS. Importance of donor selection in renal transplantation. *Med J Armed Forces India* 1994;50:205-10.
11. Lim SY, Kim MG, Park KT, Jung CW. Experiences of renal transplants from donors with renal cell carcinoma after ex vivo partial nephrectomy. *Ann Surg Treat Res* 2017;92:361-4.
12. Lim SY, Kim MG, Park KT, Jung CW. Experiences of renal transplants from donors with renal cell carcinoma after ex vivo partial nephrectomy. *Ann Surg Treat Res* 2017;92:361-4.
13. Harraz AM, Kamal AI, Shokeir AA. Urolithiasis in renal transplant donors and recipients: An update. *Int J Surg* 2016;36:693-7.
14. Kasiske BL, Ravenscraft M, Ramos EL, Gaston RS, Bia MJ, Danovitch GM. The evaluation of living renal transplant donors: clinical practice guidelines. *Ad Hoc Clinical Practice Guidelines Subcommittee of the Patient Care and Education Committee of the American Society of Transplant Physicians. J Am Soc Nephrol* 1996;7:2288-313.
15. Longo N, Calogero A, Creta M, Celentano G, Napolitano L, Capece M, et al. Outcomes of renal stone surgery performed either as predonation or ex vivo bench procedure in renal grafts from living donors: a systematic review. *Biomed Res Int* 2020;2020:6625882.
16. Pushkar P, Agarwal A, Kumar S, Guleria S. Endourological management of live donors with urolithiasis at the time of donor nephrectomy: a single center experience. *Int Urol Nephrol* 2015;47:1123-7.
17. Sarier M, Duman I, Yuksel Y, Tekin S, Ozer M, Yucetin L, et al. Ex vivo stone surgery in donor kidneys at renal transplantation. *Int J Urol* 2018;25:844-7.
18. Mosimann F, Masse M, Brunet M. Ex vivo ureteroscopy at the time of live donor nephrectomy: a word of caution. *J Endourol* 2012;26:754.